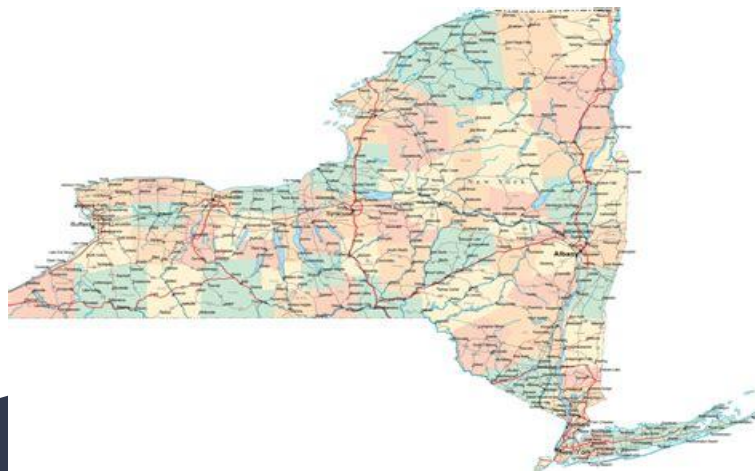

# **NEW YORK STATE'S WAY FORWARD: PATHWAYS TO HOPE AND RECOVERY WITH INSIGHTS FROM LIVED EXPERIENCE**



**Sarah Felman, The Mental Health Empowerment Project**

**Oryx Cohen, The National Empowerment Center**

# Sarah's Story

The image features a dark blue background on the left side, which transitions into a white background on the right. A thin, gold-colored diagonal line runs from the bottom left towards the center. The text "Sarah's Story" is written in a white, serif font on the dark blue background.



# St. Peter's Hospital

A Member of St. Peter's Health Care Services

St. Peter's Hospital  
315 S. Manning Blvd.  
Albany, NY 12208  
Telephone 518.525.1550

## DISCHARGE SUMMARY

<b>PATIENT NAME:</b>	SARAH FELMAN	<b>MED REC NO:</b>	1295655
<b>DOB:</b>	03/10/1994	<b>PATIENT NO:</b>	50180218733
<b>SEX:</b>	F	<b>ROOM NUMBER:</b>	5209-1
<b>ADMIT DATE:</b>	06/02/2018	<b>DISCH DATE:</b>	06/05/2018

Dictated by: Ji Ma, MD

### PRIMARY CARE PHYSICIAN:

Kevin King, M.D., the patient is a new patient to him. The first appointment will be 06/21/2018.

### HISTORY OF PRESENT ILLNESS:

Patient is a very pleasant 24-year-old female who was brought to the hospital by EMS for presumed Tylenol overdose and suicide attempt. When patient arrived to the hospital, patient was minimally responsive, although she was breathing. EMS found her with 2 bottles, 100 tab each of Tylenol PM her side.

### DISCHARGE DIAGNOSES:

1. Presumed suicidal attempt.
2. Tylenol/Benadryl overdose.
3. Altered mental status, resolved.
4. Prolonged QT, resolved, possibly due to the overdose on Tylenol and Benadryl.
5. Acute respiratory failure due to altered mental status due to drug overdose status post intubation/extubation.
6. Lactic acidosis, resolved.

### HOSPITAL COURSE:

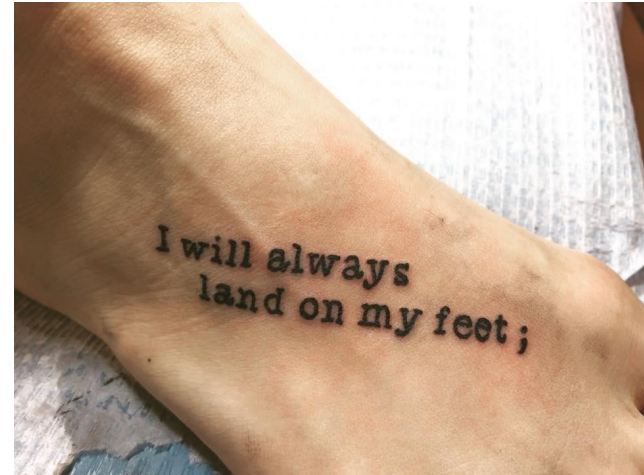The patient was found to have a significantly elevated Tylenol level in the Emergency Room of St. Peter's Hospital. Patient was admitted to ICU and started on acetylcysteine IV infusion and patient is intubated due to unresponsiveness, to protect the airway. The patient was also started on IV fluid. The Tylenol level followed which did trend down quickly back to less than 2. Patient was extubated on 06/03/2018. Patient had prolonged QT on admission. Cardiology saw the patient and felt that this is due to the drug overdose. The repeated EKG showed normalized QT. Patient's potassium was repleted. The



# Supporting Someone Through Crisis



# Finding Purpose and Healing



# Viktor E. Frankl's Theory of Logotherapy



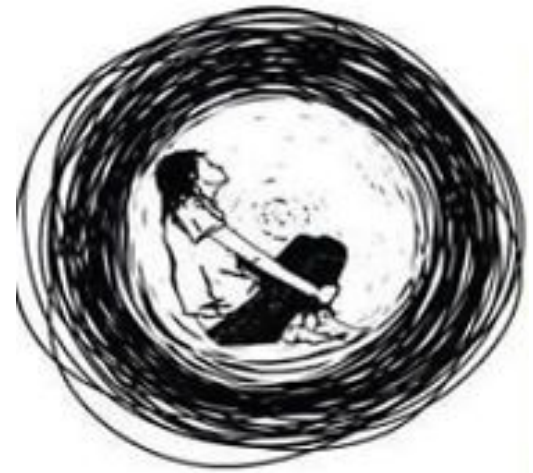“Those who have a 'why' to live, can bear with almost any 'how'.”

— Viktor E. Frankl, *Man's Search for Meaning*

# Peer Support: Empowering People to Find Their “Why”



# Alternatives to Suicide

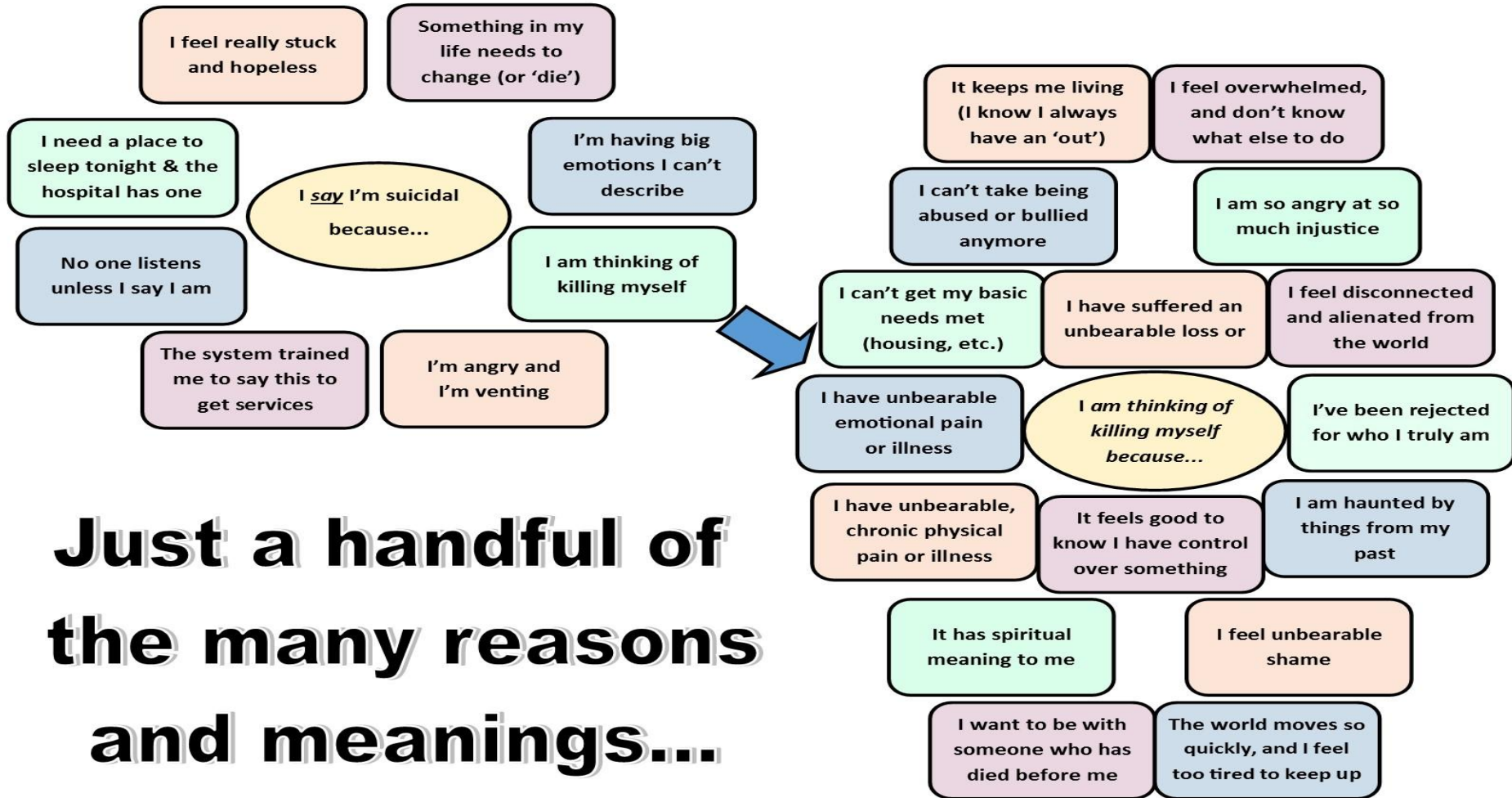

*“What does feeling suicidal mean to you?”*

Tuesdays 4:30-5:30pm at  
**The Empowerment Exchange,**  
2136 Burdett Ave. Troy, New York



518-235-2173 or  
[sfelman@mhepinc.org](mailto:sfelman@mhepinc.org)





**Just a handful of the many reasons and meanings...**

# Emotional CPR



<https://www.emotional-cpr.org/>

The Way Forward:

Listen to Us.

